

Clinical Image

Combined Effects of Constitutional and Organopathic Homeopathic Medicines for Better Improvement of Benign Prostatic Hyperplasia Cases

Paital B^{1*}, Hati AK², Nayak C, Mishra AK² and Nanda LK²

¹Department of Zoology, Orissa University of Agriculture and Technology, Bhubaneswar, India

²Dr. Abhin Chandra Homeopathic Medical College & Hospital, India

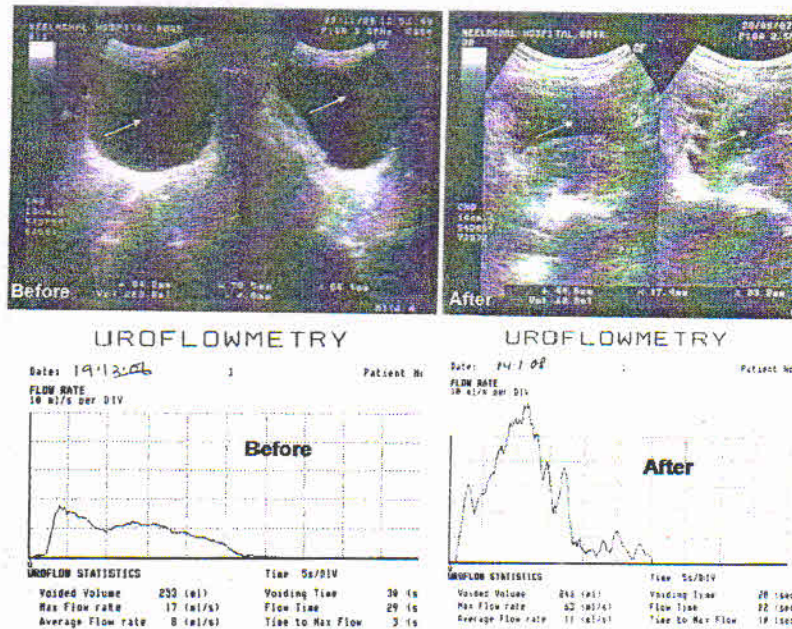


Figure 1: A representative BHP patient (number 152) of aged 70 years having residual bladder volume (indicated by white arrows) of 269 ml found before treatment (after) was reduced to 13 ml after treatment (before) when he is prescribed with BCOM.

Clinical Image

Available literature is still inadequate to rationalize the efficacy of either constitutional and/or organopathic homeopathic medicines in treating Benign Prostatic Hyperplasia (BPH). The results documented by different stalwarts are not adequate to give a clear cut demarcation between scopes and limitations in managing BPH. Hence this study was undertaken to evaluate the effects of either constitutional (Thuja, Conium, Sulph, Lycopodium, Iodium, Pulsatilla, Merc. sol., Bar. carb, Nat.mur, Lyssin, Tuberculinum, Calc. carb. Lachesis, Gelsemium, Lyssin, Tuberculinum, Carcinosisin and Staphysagria) or organopathic medicines (Sabal ser., Hydrangea., Chimaphilla., Solidago, Senecio., Triticum., Ferr. pic. and Pic. acid) prescribed alone or in combination to the patients suffering from BPH. The results obtained thereof was no doubt encouraging with alleviation of subjective symptoms like frequency, urgency, hesitancy, intermittent flow, unsatisfactory urination, feeble stream and diminution of residual urine volume. But no remarkable reduction in size of the prostate was observed with the treatment schedule. The response was better in cases of prescribing constitutional and organopathic medicines in combination than the cases taking either of them alone. Only the figure of uroflowmetry and residual void volume are given in the picture (Figure 1). A remarkable improvement case on the effect of BCOM on residual void volume as revealed from ultrasound study. A representative BHP patient (number 152) of aged 70 years having residual bladder volume (indicated by white arrows) of 269 ml found before treatment (after) was reduced to 13

*Corresponding author: Dr. Biswaranjan Paital, Department of Zoology, Orissa University of Agriculture and Technology, College of Basic Science and Humanities, Bhubaneswar-751003, Odisha, India, Tel: +91-9337413232; E-mail: biswaranjanpaital@gmail.com

Citation: Paital B, Hati AK, Nayak C, Mishra AK, Nanda LK (2017) Combined Effects of Constitutional and Organopathic Homeopathic Medicines for Better Improvement of Benign Prostatic Hyperplasia Cases. *Int J Clin Med Imaging* 4: 574. doi:10.4172/2376-0249.1000574

Copyright: © 2017 Paital B, et al. This is an open-access article distributed under the terms of the Creative Commons Attribution License, which permits unrestricted use, distribution, and reproduction in any medium, provided the original author and source are credited.